

**A CLINICO-HISTOPATHOLOGICAL STUDY OF ACQUIRED PALMOPLANTAR KERATODERMA IN A RURAL-BASED TERTIARY HOSPITAL**Sandeep Kodali<sup>1</sup>**HOW TO CITE THIS ARTICLE:**

Sandeep Kodali. "A Clinico-Histopathological Study of Acquired Palmoplantar Keratoderma in a Rural-Based Tertiary Hospital". Journal of Evolution of Medical and Dental Sciences 2014; Vol. 3, Issue 30, July 28; Page: 8500-8505, DOI: 10.14260/jemds/2014/3077

**ABSTRACT: BACKGROUND:** Palmoplantar keratodermas are a diverse group of dermatological disorders characterized by abnormal thickening of skin over palms and soles. It is classified into inherited and acquired disorders. A number of diseases have been implicated as the cause of this common and interesting group and not many studies have been done in the acquired subset of this disorder. We have undertaken this study for finding out the incidence of various etiological factors in a rural based tertiary hospital. **OBJECTIVE:** To evaluate the epidemiological, clinical, and histopathological confirmation of acquired palmoplantar keratodermas (PPKD). **MATERIALS AND METHODS:** The study population consists of 100 consecutive patients aged 10 years and above, with acquired palmoplantar keratodermas seen in Dermatology Outpatient Department in a rural based tertiary hospital. **RESULTS:** Age of the patients ranged from 11 to 75 years and the common age group was 41 – 50 years. Male predominance (1.17:1) was seen in our study and farmers, manual laborers and house-wives were most commonly affected. The dermatoses causing PPKD in our study were palmoplantar psoriasis, eczema, lichen planus and warts. A rare case of acquired palmoplantar keratoderma secondary to lichenoid drug eruption was observed by us which was not reported in literature to best of our knowledge. Many cases could not be diagnosed by histopathology; systemic examination and other investigations were normal hence were classified under idiopathic PPKD. **CONCLUSION:** Psoriasis, eczemas, lichen planus and warts were the dermatoses causing PPKD in our study. A rare case of lichenoid drug eruption causing PPKD is being reported by us, which was not reported in literature to the best of our knowledge.

**KEYWORDS:** Acquired palmoplantar keratoderma, Lichenoid drug eruption, Idiopathic acquired palmoplantar keratoderma.

**INTRODUCTION:** Palmoplantar keratodermas (PPKD) are a diverse entity of cutaneous disorders that are characterized by abnormal and excessive thickening of the skin over the palms and soles.<sup>1,2,3</sup> Palmoplantar keratodermas are traditionally classified into hereditary and acquired types and are distinguished from each other on the basis of mode of inheritance, presence of transgradiens, comorbidities with other symptoms, and extent of epidermal involvement, namely diffuse, focal, and punctate.<sup>3</sup>

Hereditary group includes epidermolytic and nonepidermolytic diffuse keratoderma, loricrin keratoderma, Mal de Meleda syndrome, pachyonychia congenita etc. <sup>1</sup> Acquired PPKD can be due to various causes, psoriasis, lichen planus, AIDS-associated, arsenic associated, corns (clavi), calluses, climacteric keratoderma, eczema, human papillomavirus, keratoderma blenorrhagicum, Norwegian scabies, paraneoplastic keratoderma, Reiter's syndrome, secondary syphilis, dermatophytosis, Sezary syndrome and tuberculosis verruca cutis.<sup>1,2,3</sup>

## ORIGINAL ARTICLE

In view of the multiple etiologies involved in this common and interesting group of diseases, and also a wide felt paucity of clinical and epidemiological studies on this subject, we have undertaken this study with an objective of finding out the incidence of various etiological factors causing acquired PPKD.

We also report a rare case of acquired PPKD, secondary to lichenoid drug eruption, which was previously unreported in the literature to the best of our knowledge.

**MATERIALS AND METHODS:** A total of 100 consecutive patients of acquired PPKD, attending the outpatient department of dermatology, venereology and leprosy in a rural based tertiary hospital in South India, from the age of 10 years and above, were included. Patients with hereditary PPKD were excluded from the study. Patients below the age of 10 years were excluded from this study because most cases of PPKD presenting below this age group belong to the hereditary type.

A complete history, with a stress on the age of onset/ duration of symptoms, exacerbations and remissions, family history of similar disease and history of any other previous or concomitant illnesses was recorded. A complete general, systemic and cutaneous examination was done with reference to lesions on the other parts of the body, any other dermatoses or systemic diseases. Skin biopsy was done in all the patients.

Routine investigations like complete blood picture, complete urine examination, random blood sugar, serum creatinine and other tests like thyroid profile, VDRL, HIV 1 & 2 antibodies, potassium hydroxide mount of skin scrapings, PAS staining of biopsy section, chest radiographs and ultrasound abdomen were done wherever necessary.

**OBSERVATIONS AND RESULTS:** A total of 100 consecutive patients of acquired palmoplantar keratoderma fulfilling the inclusion criteria, attending the outpatient department of dermatology, venereology and leprosy at a rural based tertiary hospital were included.

Age of the patients ranged from 11 to 75 years (mean age being 43.72). Most number of patients belonged to age group of 41 – 50 years (26.00 %), followed by the age group of 21–30 years (24.00 %). The least number of patients were seen in the age group of 71–80 years (1.00 %). (Table 1).

AGEGROUP (YEARS)	NUMBER OF PATIENTS	PERCENT
11 – 20 years	9	9.00
21 – 30 years	24	24.00
31 – 40 years	19	19.00
41 – 50 years	26	26.00
51 – 60 years	16	16.00
61 – 70 years	5	5.00
71 – 80 years	1	1.00
<b>TOTAL</b>	<b>100</b>	<b>100.00</b>

The onset of the disease was in 21 – 40 years age group in majority of the patients. Out of the total 100 patients studied, 54.00 % were male and 46.00 % were female patients. Male to female ratio was 1.17 showing male preponderance. Occurrence of PPK was mostly seen among farmers (45.00 %), followed by house-wives, manual laborers and weavers (7.00 %). (Table 2)

## ORIGINAL ARTICLE

---

OCCUPATION	NUMBER	PERCENT
Agriculture	45	45.00
House wife	20	20.00
Manual laborers	8	8.00
Student	8	8.00
Weaver	7	7.00
Shepherd	5	5.00
Unemployed	5	5.00
Attender	1	1.00
Nurse	1	1.00
<b>TOTAL</b>	<b>100</b>	<b>100.00</b>

Involvement of both palms and soles was seen in 60.00 % of cases, followed by only soles in 25.00 % and on only palms in 15.00 % of the cases. Bilateral symmetry was seen in 91.00 % of the cases. Itching was the predominant symptom in majority of the patients (90.00 %), followed by pain and fissuring (75.00 %). Seasonal exacerbation of the disease was seen, both in the winter (40.00 %) as well as in summer season (20.00 %).

Out of a total of 100 cases studied, clinically 52 patients (52.00 %) were diagnosed as psoriasis, 31 patients (31.00 %) as eczema, 11 patients were diagnosed (11.00 %) as lichen planus, two patients (2.00 %) as fungal infection, two patients (2.00 %) as leprosy and one patient (1.00 %) as verruca vulgaris. One case of lichenoid eruption presenting as PPKD was seen in a patient having violaceous to hyper pigmented macules over the face and both upper and lower limbs.

Patient was a known epileptic from 20 years. Her medication was changed from phenytoin to carbamazepine and she started developing pigmented papules and plaques over both soles from 4 weeks of initiation of treatment. (Figure 1) Histopathologically, out of 52 psoriasis patients, 31 showed typical changes of psoriasis, while 20 out of 31 patients showed typical changes of eczema and 8 patients out of 11 patients showed typical changes of lichen planus. Biopsy of the lichenoid drug eruption from the sole confirmed our diagnosis of lichenoid drug eruption. (Figure 2) After replacing this drug, these lesions subsided within a period of 4 weeks.

Verruca vulgaris lesions were confirmed histopathologically in one case diagnosed clinically. (1.00 %) Fungal infection was suspected in two cases of palmoplantar keratoderma, which was positive for potassium hydroxide mount but the biopsy was non-specific. Leprosy was suspected to be the cause of two cases of palmoplantar keratoderma but again the histopathology was non-specific. (Table 3)

## ORIGINAL ARTICLE

DISEASE	NUMBER	
	CLINICAL	HISTOPATHOLOGY
PSORIASIS	52 (52.00 %)	31 (31.00 %)
ECZEMA	31 (31.00 %)	20 (20.00 %)
LICHEN PLANUS	11 (11.00 %)	8 (8.00 %)
LICHENOID ERUPTION	1 (1.00 %)	1 (1.00 %)
FUNGAL	2 (2.00 %)	0
VERRUCA	1 (1.00 %)	1 (1.00 %)
LEPROSY	2 (2.00 %)	0
NON-SPECIFIC		39 (39.00 %)
<b>TOTAL</b>	<b>100</b>	<b>100.00</b>

**DISCUSSION:** A total of 100 clinically diagnosed cases of palmoplantar keratoderma attending the outpatient department of dermatology, STD and leprosy in a rural based tertiary hospital were studied for the clinico-histopathological correlation.

In the present study on acquired palmoplantar keratoderma, the patients were studied for the age and sex distribution, etiology and the histopathology of the diseases.

In our study, most of the cases (26.00%) belonged to the age group of 41-50 years. Presentation of acquired palmoplantar keratoderma in later years of life maybe due to the fact that the cumulative insult of constant exposure to trauma, allergens and irritants may produce keratoderma.<sup>4</sup>

In our study male preponderance was seen (males 54.00%, females 46.00%) which is in concordance with previous studies. In a study by Mahajan PM et al,<sup>4</sup> 64.63% of cases were males. Similarly, Chopra et al<sup>5</sup> reported male preponderance in their study of acquired PPKD, where 55.00% of the cases were males. This male preponderance of palmoplantar keratoderma is probably due to various outdoor occupations and activities resulting in predisposition to trauma caused by manual labor and working or walking barefoot.

Chopra et al,<sup>4</sup> in their study of palmoplantar keratoderma, showed that in occupation-wise distribution, different types of manual workers such as laborers, farmers and mechanical workers contributed to 48.16% and housewives - 18.69%. This is in concordance with our study where farmers (53.00 %) were mainly affected, followed by house-wives (20.00 %). Farmers and manual laborers are engaged in strenuous physical work and are exposed to various forms of trauma, friction and chemicals. High incidence of palmoplantar keratoderma among manual workers was in accordance to the usual belief that hyperkeratosis of palms and soles will be more common in the working class.<sup>5</sup> Housewives are exposed to various detergents and vegetable juices when engaged in house-hold activities which may cause keratoderma over the palms and soles.

Exacerbation of palmoplantar keratoderma in both winter and summer seasons in our study was in concordance with the study done by Mahajan et al.<sup>4</sup> This feature could be explained on the basis that extremes of climatic conditions and temperature are known to exacerbate palmoplantar keratoderma.

## ORIGINAL ARTICLE

---

Similarly, this exacerbation in particular season also depends upon the remission and exacerbation of the disease causing palmoplantar keratoderma in particular seasons.

In our study, among all the diseases causing palmoplantar keratoderma, the most probable diagnosis was considered for each case after clinical examination such as psoriasis, lichen planus, eczema, fungal infections and warts respectively. Out of 55 cases (55.00%) clinically diagnosed as psoriasis, 31 cases (31.00%) were histopathologically proved.

In the study done by Mahajan et al,<sup>4</sup> psoriasis was found to be 31.11 % among all acquired causes, which was in concordance with our study. Out of 31(31.00%) cases of eczema clinically diagnosed, 20(20.00%) were proved histopathologically. Lichen planus was the main clinical diagnosis in 11 cases, which correlated histopathologically in 8 (8.00 %) cases.

This was again in concordance with the acquired causes of PPKD in the study done by Mahajan PM (8.8 %).<sup>4</sup> Two cases of fungal infection were diagnosed clinically and by KOH mount but were histopathologically inconclusive. A case of verruca vulgaris (1.00%) was clinically diagnosed and were also proved histopathologically which was similar as in the above mentioned study by Mahajan PM (2.00%).<sup>4</sup>

One case of lichenoid eruption secondary to carbamazepine, presented as palmoplantar keratoderma and this was confirmed by histopathological examination of the biopsy. Lichenoid eruption occurring as a palmoplantar keratoderma due to a drug (carbamazepine) is very rare and no study has mentioned it to the best of our knowledge.

Among the 100 cases studied, 39 cases were histopathologically inconclusive. Complete examination of the other systems was normal. All the hematological and biochemical investigations including screening for syphilis were normal. Radiological workup like chest radiography, ultrasound abdomen was also normal. These cases were classified as idiopathic PPKD.

**CONCLUSION:** Male predominance was seen in our study and 41 – 50 year age group was the most common age group involved. Psoriasis, eczema, lichen planus and warts were the dermatoses causing acquired PPKD in our study. The cause of many cases could not be determined by local and systemic examination and by investigations, hence classified under Idiopathic PPKD.

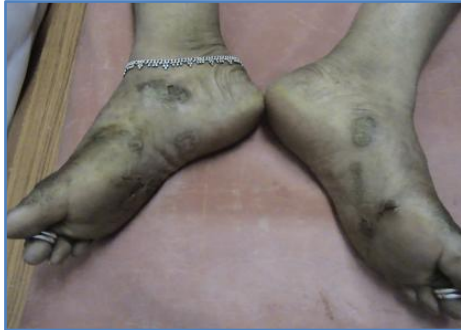Idiopathic acquired PPK should be reserved as a diagnosis of exclusion, when all other etiologies have been investigated and ruled out, including dermatoses, drugs, systemic diseases, infectious diseases and malignancies. We are reporting a rare case of lichenoid drug eruption presenting as plantar keratoderma due to carbamazepine, which was previously not reported in literature to the best of our knowledge.

### REFERENCES:

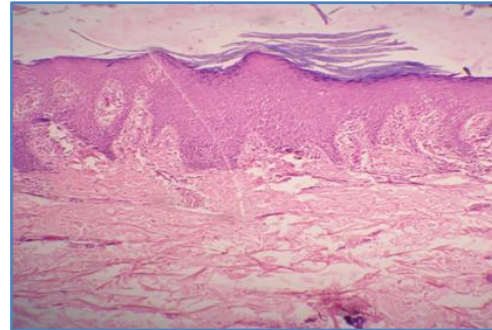
1. Judge MR, McLean WHI, Munro CS. Disorders of keratinization. In: Burns T, Breathnac S, Cox N, Griffiths C. Rook's Textbook of Dermatology. 7th ed. Blackwell Publishing Company; 2004.p.34.1-111.
2. Stevens HP, Kelsell DP, Leigh IM. The inherited keratodermas of palms and soles. IN: Freedberg IM, Eisen AZ, Wolff K, Austen KF, Goldsmith LA, Katz SI. Fitzpatrick's Dermatology in general medicine. 6th ed. Mc-Graw-Hill Companies, Inc.; 2003.p.506.
3. Patel S, Zirwas M, English JC. Acquired Palmoplantar Keratoderma. American Journal of Clinical Dermatology, Volume 8, Number 1, 2007, pp. 1-11 (11).

## ORIGINAL ARTICLE

4. Mahajan PM, Gharpuray MB, Kulkarni V. Clinical and histopathological study of palmoplantar keratoderma. Indian J Dermatol Venereol Leprol 1994; 60: 258-261.
5. Chopra A, Maninder, Gill SS. Hyperkeratosis of palms and soles: clinical study. Indian J Dermatol Venereol Leprol 1997; 63: 85-8.



**Fig. 1: Hyperpigmented plaques on the soles – lichenoid drug eruption**



**Fig. 2: Histopathology showing features of lichenoid drug eruption**

### **AUTHORS:**

1. Sandeep Kodali

### **PARTICULARS OF CONTRIBUTORS:**

1. Assistant Professor, Department of DVL, GSL Medical College and General Hospital.

### **NAME ADDRESS EMAIL ID OF THE CORRESPONDING AUTHOR:**

Dr. Sandeep Kodali,  
Assistant Professor,  
Department of DVL,  
GSL Medical College and General Hospital,  
NH-16, Lakshmipuram, Rajanagaram,  
Rajahmundry, East Godavari District-533296,  
Andhra Pradesh.  
Email: sandeep\_kodali@yahoo.com

Date of Submission: 07/07/2014.

Date of Peer Review: 08/07/2014.

Date of Acceptance: 17/07/2014.

Date of Publishing: 26/07/2014.